

GIANT ANEURYSM OF THE AZYGOS PERICALLOSAL ARTERY: CASE REPORT AND REVIEW OF THE LITERATURE

Cahide Topsakal, M.D.,* M. Faik Ozveren, M.D.,* Fatih S. Erol, M.D.,*
Mutlu Cihangiroglu, M.D.,† and Hasan Cetin, M.D.*

*Departments of Neurosurgery and †Radiology, Firat University, School of Medicine,
Elazig, Turkey

Topsakal C, Ozveren MF, Erol FS, Cihangiroglu M, Cetin H. Giant aneurysm of the azygos pericallosal artery: case report and review of the literature. *Surg Neurol* 2003;60:524–33.

BACKGROUND

Pericallosal aneurysms are encountered less than 6.7%, and giant aneurysms among them even less. Giant azygos pericallosal artery aneurysm at the callosomarginal bifurcation is extremely rare, and our case presented herein is the second one. The case is discussed with thorough review of the literature.

METHODS

A 65-year-old woman presented with an extremely rare giant aneurysm on the azygos pericallosal artery manifesting as subarachnoid hemorrhage in World Federation of Neurosurgical Societies Grade 3. Computed tomography (CT), magnetic resonance angiography (MRA), and four vessel angiography revealed a giant azygos pericallosal artery aneurysm associated with a second aneurysm at the left M1.

RESULTS

After recovery to Grade 2, she underwent surgery via the right frontal interhemispheric approach for the azygos artery aneurysm on the 17th day after bleeding. The true dimensions of the aneurysm were greater than indicated by angiography because of partial thrombosis. Trilobulate aneurysm was carefully dissected from the surrounding structures. Postoperative cerebral angiography showed no filling of the clipped aneurysm and preservation of circulation.

CONCLUSION

The treatment of distal anterior cerebral artery aneurysms is often difficult, because of their broad-based irregular configurations and adherence to surrounding tissue, tendency to bleed irrespective of size and the coexistence of other cerebral aneurysms. However, excellent outcomes can be obtained based on thorough preoperative radiologic evaluation, including magnetic resonance imaging (MRI), and correct selection of surgical approach. © 2003 Elsevier Inc. All rights reserved.

KEY WORDS

Azygos pericallosal artery, cerebral aneurysm, cerebral angiography, distal anterior cerebral artery, pericallosal aneurysm.

The anterior cerebral arteries (ACAs) may unite to form a common single trunk, which is called the azygos or unpaired ACA, a rare vascular configuration in human anatomy (0–5%) [2,24,32,42,43,79]. The incidence of aneurysms of the distal ACA is less than 5 to 8.7% [24,39,51,54,63,77,80] and association with azygos pericallosal artery is very rare [24,38,42,51,57,79]. Coexistence of giant aneurysms is much less common [20]. Distal ACA aneurysms are difficult to handle surgically, so the differential diagnosis, as well as the associated vascular anomalies, requires careful attention.

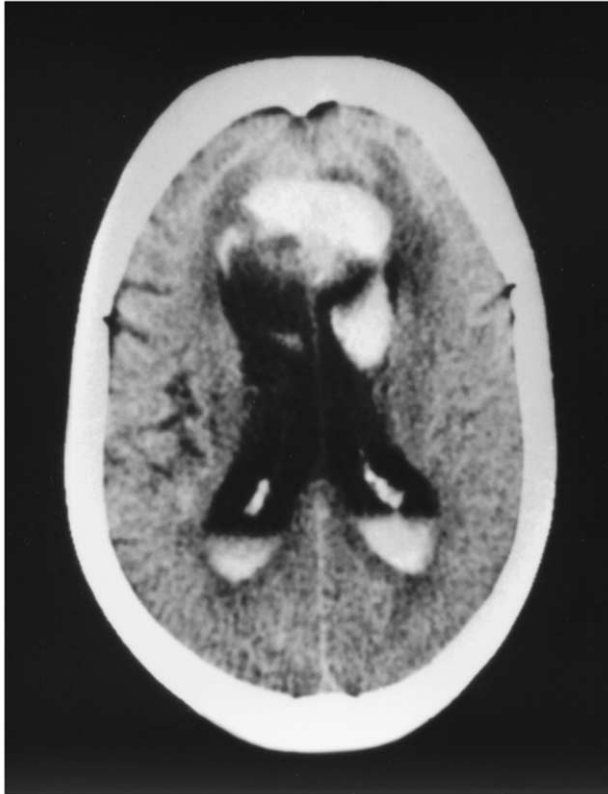We treated an elderly woman with a giant aneurysm of the azygos pericallosal artery identified by computed tomography (CT), magnetic resonance angiography (MRA), and digital subtraction angiography (DSA).

CASE REPORT

A 65-year-old woman was referred to our clinic from the Department of Neurology in June 1997 because of a second episode of subarachnoid hemorrhage. She was admitted on the 7th day after bleeding. Her first attack had occurred 2 months previously, and was treated conservatively.

Physical examination found she was somnolent with mild left hemiparesis and was evaluated as World Federation of Neurosurgical Societies (WFNS) Grade 3 [12]. CT revealed the presence of blood in the interhemispheric fissure with widespread subarachnoid hemorrhage and callosal he-

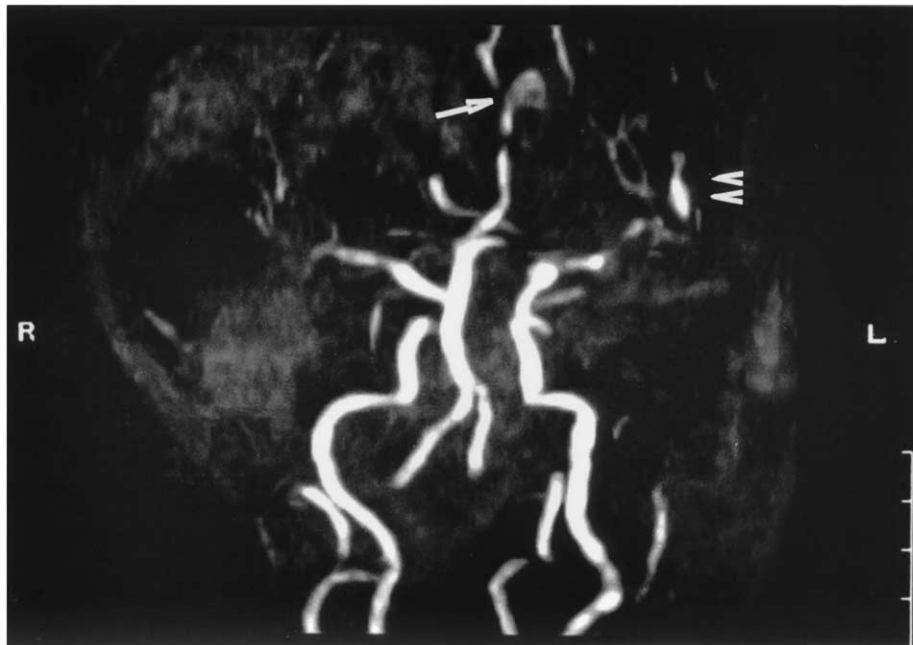Address reprint requests to: Dr. Cahide Topsakal, Firat Universitesi Tip Fakultesi, Norosirurji Departmani, 23100 Elazig, Turkey.
Received August 7, 2002; accepted February 24, 2003.



1 Axial computed tomography scan showing the callosal hematoma predominantly on the left side with widespread subarachnoid and intraventricular hemorrhage.

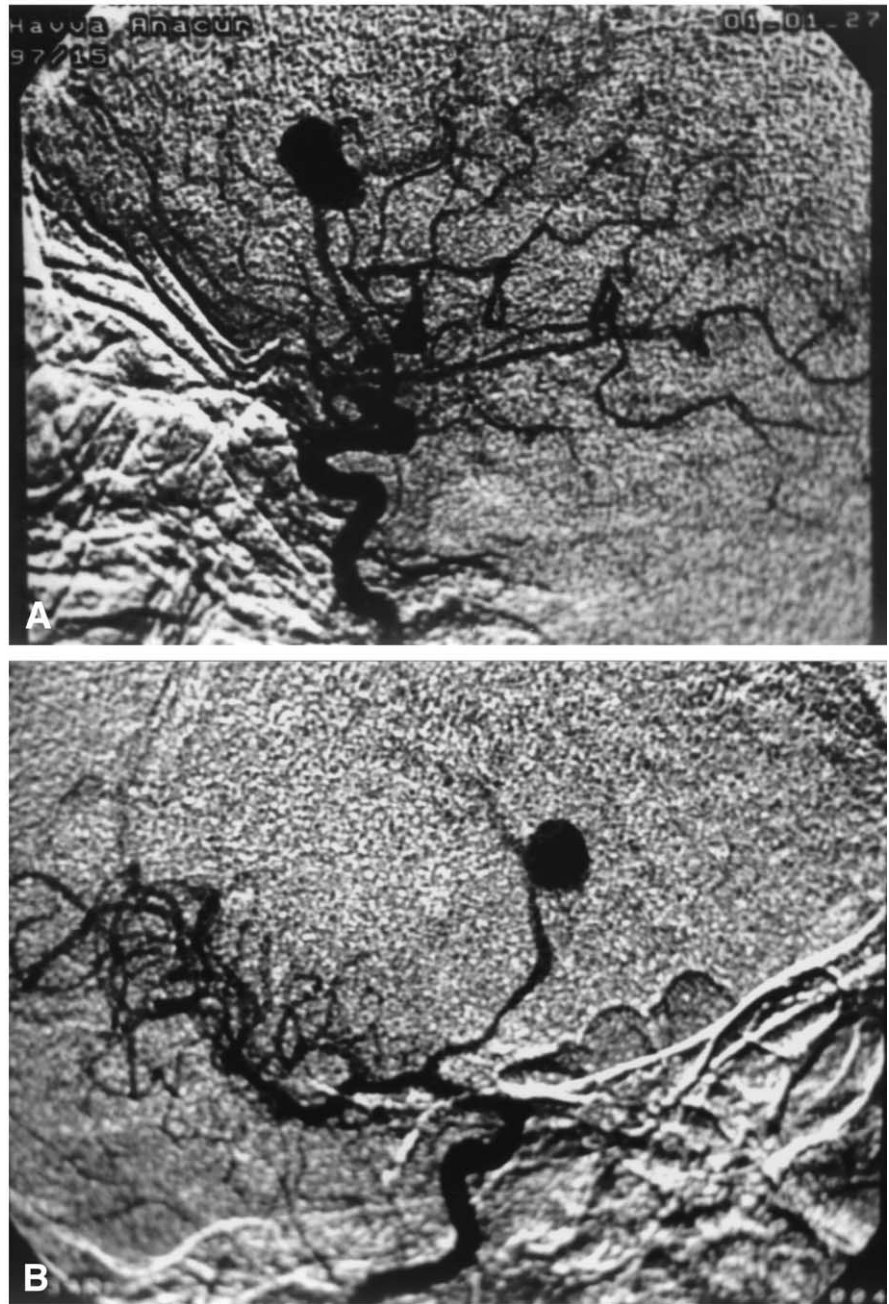
matoma extending into the lateral ventricles (Figure 1). MRA revealed an aneurysmatic dilatation at the callosomarginal bifurcation of the distal ACA (Figure 2). Four-vessel angiography revealed an azygos distal ACA with a giant aneurysm located at the callosomarginal bifurcation of the azygos pericallosal artery. The aneurysm was broad based, trilobulate with irregular configuration, and $25 \times 15 \times 15$ mm in size. Another aneurysmatic dilatation was observed at the left M2 (Figure 3). Surgery was performed on the 17th day after bleeding, as soon as she recovered to WFNS Grade 2.

Right frontal paramedian craniotomy was performed across the anterior third of superior sagittal sinus and a U-shaped dural flap reflected to the left side based on the sinus to give access to the interhemispheric fissure. The self-retaining retractors were gently interplated in the fissure between the bridging anterior and middle frontal veins. We proceeded along the shallow falx down to the lower edge by suctioning the clots. Clearing of the arachnoid adhesions between cingulate gyri exposed the single distal ACA (pericallosal) and two ramifications on both sides in the callosal cistern. We proceeded proximally, and the trilobulate giant aneurysm emerged at the callosomarginal bifurcation of pericallosal artery. The actual dimensions of the aneurysm were greater than the angiographic dimensions. Each lobule extended in a different direction, one adherent to the left cingulate gyrus at the



2 MRA revealing the azygos anterior cerebral artery associated with an aneurysm at the distal end (white arrow). A second aneurysm is seen on the left middle cerebral artery (double white arrowheads).

3 (A) Left lateral carotid angiogram showing the giant anterior cerebral artery aneurysm extending superiorly at the level of the genu of the corpus callosum or callosomarginal artery bifurcation. The proximal part of the callosomarginal artery is demonstrated. Note the second aneurysm on the left middle cerebral artery. (B) Right oblique carotid angiogram.



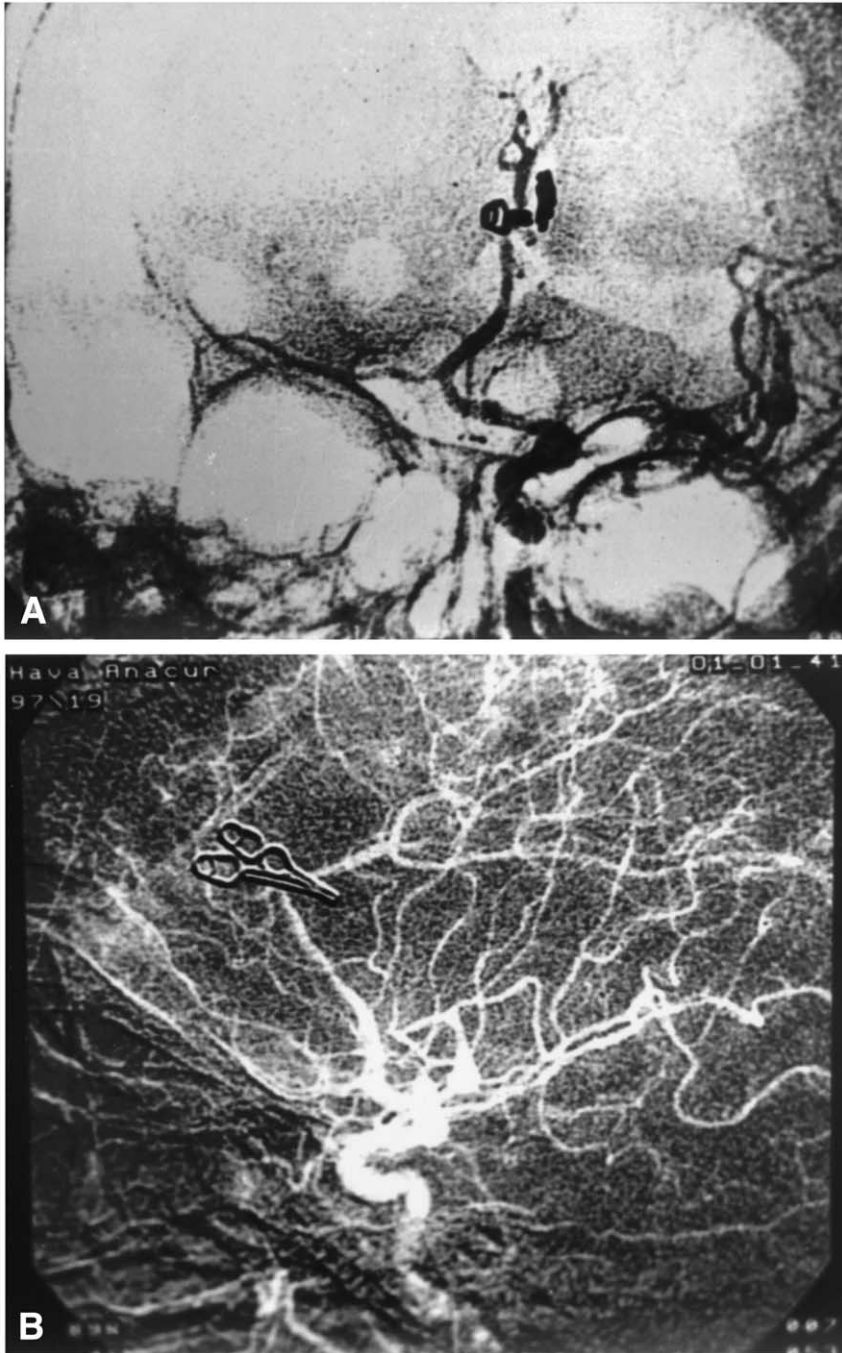
bleeding point, and another fully filled with thrombus extending to the base. The parent arteries were exposed proximal to aneurysm. The neck was broad based. After clearing the adhesions to the surrounding tissue and preparing the neck, we placed two Yasargil aneurysm clips without compromising the parent arteries.

No neurologic deficit developed after the surgery, and postoperative carotid angiography showed good circulation in the parent arteries without filling of the aneurysm (Figure 4). The patient recovered within hours, and did not develop any neuro-

logic deficit all through the first month, but subsequently died of pulmonary embolus because of thrombophlebitis.

DISCUSSION

Generally, pericallosal (distal ACA) aneurysms are rare, representing only 2 to 6.7% of all intracranial aneurysms [26,39,54,63,77,80,81]. Giant intracranial aneurysms (>2.5 cm) account for 3 to 13% of all intracranial aneurysms [3,11,20,41,57,69,76,79,80].



4 (A) Postoperative left anteroposterior carotid angiogram with cross compression showing the azygos pericallosal artery aneurysm not filled because of two perpendicular aneurysm clips. The trifurcation of the pericallosal artery is located distal to the aneurysm. The azygos pericallosal artery and hypoplastic or vasospastic right A1 are displayed very well by cross compression. (B) Postoperative left lateral carotid angiogram.

Giant pericallosal aneurysms are very rare and somehow are not mentioned in the large series of either giant aneurysms [66,69,76,77,80] or pericallosal aneurysms [23,26,54,63,76,81]. In the literature there have been only 13 cases of giant pericallosal artery aneurysms [11,14,20,21,23,45,52,55,56,58,59,64,73], and our case is the 14th. Association of saccular aneurysm with azygos pericallosal artery is <13% (Table 1) [1,5-7,13,14,16-20,24,27,29,31,32,35-43,46,47,51,53,57,61,62,70,72,77-79]. Giant azy-

gos pericallosal artery aneurysm is extremely rare [19,20,46,62,78], particularly at the callosomarginal bifurcation, and out of 6 giant azygos pericallosal aneurysms, ours is the second case reported at this location.

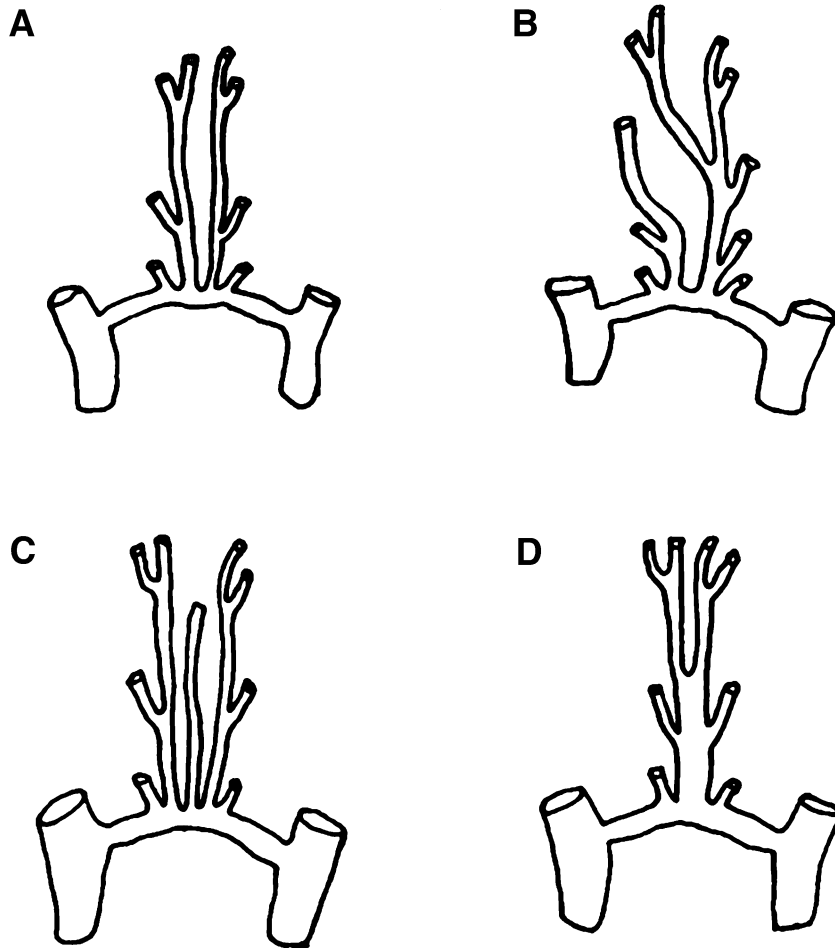
Various degrees of fusion of the ACAs have been described, from limited or punctiform contact to a common trunk [2]. The incidence of the true azygos distal ACA (Baptista Type 3), from which all major branches are given off to both hemispheres, ranges

1 Reported Cases of Aneurysm of the Azygos Pericallosal Artery

AUTHOR	YEAR	NO. OF CASES	LOCATION
Laitinen and Snellman	(1960)[39]	3	distal end
Pool and Potts	(1965)[57]	3	distal end
Le May and Gooding	(1966)[42]	1	proximal end
Takahashi	(1967)[29]	1	unknown
Okawara	(1968)[53]	1	distal end
Kitamura	(1970)[36]	1	distal end
Ishii et al	(1974)[27]	1	distal end
Kinoshita and Matsukado	(1975)[35]	2	1 distal, 1 middle
Yamada	(1975)[29]	1	distal end
Yamagata	(1975)[29]	1	proximal end
Katz et al.	(1978)[32]	1	distal end
Fankhauser and Zander	(1978)[13]	1	distal end
Nukui	(1978)[29]	1	distal end
Dennis	(1979)[29]	1	distal end
Egami	(1979)[29]	1	distal end
Kondo et al	(1979)[38]	1	distal end
Huber et al	(1980)[24]	2	distal end
Fujimoto et al	(1981)[16]	1	rt distal callosomarginal bifurcation
Niizuma et al	(1981)[51]	2	1 distal, 1 middle
Fukawa et al	(1982)[17]	1	unknown
Mochizuki et al	(1982)[47]	1	proximal end
Benedetti and Curri	(1983)[5]	1	distal end
Yasargil	(1984)[79]	2	distal end
Lau et al	(1984)[40]	1	distal end-callosomarginal bifurcation
Hayashi et al	(1985)[20]	2	distal end (giant)
Abe et al	(1985)[1]	2	1 distal, 1 proximal 4 distal, 1 middle, 1 callosomarginal
Kaneko et al	(1985)[29]	7	bifurcation, 1 proximal
Yamagami et al	(1986)[78]	1	distal end-callosomarginal bifurcation (giant)
Kobayashi et al	(1986)[37]	1	proximal end
Kato	(1986)[31]	1	unknown
Harada et al	(1987)[18]	1	distal end
Wisoff and Flamm	(1987)[77]	2	unknown
Schick and Rumbaugh	(1989)[61]	1	distal end
Lightfoote et al	(1989)[43]	1	proximal end
Mishima et al	(1990)[46]	1	distal end (giant)
Calzolari et al	(1991)[6]	1	callosomarginal bifurcation
Cinnamon et al	(1992)[7]	1	distal end-trifurcation
Hashizume et al	(1992)[19]	1	distal end (giant)
Traynelis and Dunker	(1992)[72]	1	distal end (3 aneurysms)
Shiokawa et al	(1993)[62]	1	(giant)
Zderkiewicz et al	(1992)[82]	1	not available
Baykal S et al	(1996)[4]	2	callosomarginal bifurcation
Suzuki et al	(1998)[70]	1	distal end-supracallosal
Dietrich et al	(2000)[10]	1	callosomarginal bifurcation
Present case		1	callosomarginal bifurcation (giant)

from 0 to 5% [2,24,32,42,43,79]. True azygos distal ACA must be distinguished angiographically from the more common (incidence 12%) so-called azygos distal ACA (Baptista Type 1), or bihemispheric pericallosal artery, in which both ACAs are present, one being hypoplastic and most of the branches to both hemispheres arising from the other. A carotid angiography with contralateral compression, rather than a bilateral carotid angiography, is more appropriate for identification of an azygos artery [5,47,51,78], allowing discrimination from the bi-

hemispheric variant and display of the median anterior arterial vascularization and all components in greater detail [5]. The clinical importance of a correct diagnosis of azygos distal ACA arises from the presence of a single trunk, which supplies blood to both hemispheres [32,42]. Occlusion of this single trunk as a result of thromboembolic disease, vasospasm, or surgical error has disastrous effects [6,32,42]. There are other types of vascular anomalies, such as Baptista Type 2, a triple ACA with the accessory ACA or corpus callosum median artery



5 Anatomic variants of the anterior cerebral artery. (A) Normal configuration, (B) bi-hemispheric pericallosal artery, (C) triple anterior cerebral artery or corpus callosum median artery, (D) azygos pericallosal/distal anterior cerebral artery.

arising from the anterior communicating artery (AcoA) (9.6–13%) [2,79]. Baptista Types 2 and 3 are frequently observed at one of the stages of embryonic development, which involves either duplication of the common trunk or involution of the median branch [32,42,71]. Type 3 may result from the persistence of the artery of the corpus callosum with reabsorption of the two ACAs or arise from the direct fusion of the two arteries (Figure 5). Azygos pericallosal artery associated with midline malformations of the central nervous system such as agenesis of corpus callosum, holoprosencephaly [32,42,59], and association with arteriovenous malformation [18,20,24,57,59,77] suggest that the arterial anomaly might be related to embryological development. However, our patient had no associated midline malformations. Association of azygos pericallosal artery with berry aneurysms may be as high as 41.1 to 71% of the azygos pericallosal arteries [24,42,51,57,79].

Aneurysms not associated with azygos artery usually occur at the level of the genu of the corpus

callosum, where the pericallosal artery sharply arches posteriorly, i.e., the callosomarginal bifurcation 69 to 78% [21,39,77,80] and then the frontopolar artery, whereas very proximal and distal locations are rare, and frontobasal is the rarest [11,21]. Aneurysms associated with azygos distal ACA are usually located at the distal end of the azygos pericallosal artery [7,16,24,32,35,36,38,39,42], generally at the callosomarginal bifurcation [6,16,35,51], as in our case, or trifurcation. The proximal location is rare [42]. Associated vascular anomalies and the variations in the circle of Willis [33,67] with marked effects on circulatory dynamics may be involved in the formation of the aneurysm [37,42,51,54,61,62]. Geometric changes from the symmetrical to asymmetrical arterial junction develop higher shear stress than critical values and the stagnation point at the junction [75]. The branching geometry determines significant increase of shear stress at the branching sites of cerebral arteries in patients with aneurysm of the DACA compared to normal controls [60]. The burden of blood flow from the

bilateral A1 on the end of anomalous azygos artery is responsible for aneurysm development [51].

In an arterial network, the pressures and shear stresses that develop along the outer wall of a curved artery, and the apex of an arterial bifurcation create a hemodynamic state that promotes saccular aneurysm formation [15,60]. Additionally, geometrical relation between aneurysm and parent vessels is the primary factor governing the intra-aneurysmal flow pattern [68]. For uneven branch flow, flow activity inside the aneurysm and the stresses acting on the aneurysmal wall increase with increasing bifurcation angle, and may cause aneurysm rupture [44]. It is less susceptible to thrombus formation, because both sides of the aneurysm neck are subjected to increased states of hemodynamic stress, one arising from the pressure and the other from the shear on the side of the larger and the smaller daughter branches, respectively [15]. On the other hand, for evenly distributed branch flow, as is valid in our case, the intra-aneurysmal flow is sluggish and therefore, prone to thrombosis for all studied bifurcation angles [44]. In our case, the broad-based and giant aneurysm was trilobulate, with every lobule oriented in a different direction. The largest lobule was directed to the left and embedded into the left cingulate gyri, and full of thrombus, so the dimensions were underestimated on MRA and DSA [58,74].

Giant pericallosal aneurysms are encountered very seldom, possibly because of the tendency to early rupture and treatment before enlargement [63]. Giant aneurysms tend to thrombose and are invisible on angiography [58]. Therefore, MRI is superior to CT and DSA for evaluating the characteristics of aneurysms and provides additional information about the condition of the surrounding brain [45,48,59]. MR imaging shows giant aneurysm as a large, round, nonhomogeneous intensity area, with a patent lumen appearing as signal void and thrombosis as hyperintense areas. More recently thrombosed aneurysm appears as more homogeneous with a density similar to that of coagulated blood and therefore, may be indistinguishable from hematoma on CT, allowing the membrane of the hematoma to mimic a tumor [40,45]. In our case, because we could not provide intraoperative MRI, we were confronted with problems all through the surgery because of the underestimation of its exact dimensions. Hematoma is seen in 60.9 to 67% of cases of distal ACA aneurysm, of which half are callosal hematoma, and more than half of these cases are associated with intraventricular hematoma [28,80]. In our case, the callosal hematoma extended into the lateral ventricles.

Patients with distal ACA aneurysm have multiple aneurysms at rates of 5–55% [21,54,63,77,80]. Most cases (68–83%) are located on the middle cerebral artery and at the contralateral ACA (mirror aneurysm) [39,48,50,65,77,80], and 10.4% on the AcoA [54]. In our case, a second aneurysm was found on the left M2.

In general, distal ACA aneurysms have a worse prognosis than those of other sites of the anterior circulation [63] since they are fragile and rupture prematurely during exposure, resulting in a higher morbidity than expected from the angiographic appearance and location [8]. Patients with distal ACA aneurysm associated with multiple aneurysms suffer bleeding in 30 to 50% of cases [25]. Bleeding occurs irrespective of their size because of the lack of resistant arachnoid membranes at the level of the pericallosal cisterns [54,63]. Distal ACA aneurysm presents special difficulties for the surgeon because of the association of the azygos ACA and multiple aneurysms, including the narrow working space in the interhemispheric fissure and the callosal cistern, dense adhesions between the cingulate gyri, a broad-based and/or a sclerotic neck in the aneurysms, difficulty in identifying the parent artery, and the fixed dome on the pial layer limiting lateral retraction of the right hemisphere to a few millimeters [80]. We experienced similar difficulties during surgery [21,48,54,80]. Surgery of aneurysms at the origin of the callosomarginal artery is technically difficult, because this portion of the ACA lies beneath the corpus callosum. Cingulate resection for pericallosal aneurysms [22] or partial callosal resection, either along the commissure or genu [39], is recommended to gain control of the ACA proximal to the origin of callosomarginal artery without causing disconnection syndrome [9,45,72]. Lateral right frontal approach with amputation of the frontal pole avoids traumatic maneuvers on the medial surface of the frontal lobes [5]. Good results were obtained with anterior frontal trephine and interhemispheric dissection [34]. We favored unilateral interhemispheric exposure [8,18,20,70] to treat the pericallosal aneurysm and left the other aneurysm for further operation to reduce the risk of mortality [8]. We approached from the distal to proximal direction, not to confuse the parent arteries.

Handling giant pericallosal aneurysms are rare, particularly in association with azygos pericallosal artery. Preoperative difficulties include the tendency to bleed irrespective of size and invisibility on angiography, and surgical difficulties include the broad base and adherence to the surrounding tissues, which make clipping cumbersome. Preoperative radiologic examinations are extremely impor-

tant for good surgery. They include examinations not only of the internal shape on angiograms, but also the outer shape of aneurysm demonstrated by MRI, because inside of a large aneurysm partial thrombosis, like in this case, is frequent. Proper preoperative evaluation and surgical approach with the use of microsurgical techniques and minimal retraction of the brain and preservation of the bridging veins will reduce the risk of postoperative mortality and morbidity to an acceptable level [63].

REFERENCES

1. Abe S, Fujii K, Nishimura K, Kurokawa K. [Azygos anterior cerebral artery aneurysm. Report of two cases.] *Neurol Med Chir (Tokyo)* 1985;25:215-8 (Jpn, with Eng abstract).
2. Baptista AG. Studies on the arteries of the brain II. The anterior cerebral artery: some anatomic features and their clinical implications. *Neurology* 1963;13:825-35.
3. Batjer, HH, Kopitnik, TA, Pardy, PD, Samson, DS, Meyer, DM. Giant cerebral aneurysms. In: Awad IA, ed. *Current Management of Cerebral Aneurysms*. Rolling Meadows: American Association of Neurological Surgeons, 1993;177-98.
4. Baykal S, Ceylan S, Dinc H, Soylev E, Usul H, Akturk F. Aneurysm of an azygos anterior cerebral artery: report of two cases and review of the literature. *Neurosurg Rev* 1996;19:57-9.
5. Benedetti A, Curri D. Aneurysm of azygos anterior cerebral artery. *Neurochirurgia (Stuttg)* 1983;26:56-8.
6. Calzolari F, Ceruti S, Pinna L, Tamarozzi R. Aneurysm of the azygos pericallosal artery. *J Neuroradiol* 1991;18:277-85.
7. Cinnamon J, Zito J, Chalif DJ, et al. Aneurysm of the azygos pericallosal artery: diagnosis by MR imaging and MR angiography. *AJNR Am J Neuroradiol* 1992;13:280-2.
8. De Sousa AA, Dantas FL, de Cardoso GT, Costa BS. Distal anterior cerebral artery aneurysms. *Surg Neurol* 1999;52:128-36.
9. Dickey PS, Bloomgarden GM, Arkins TJ, Spencer DD. Partial callosal resection for pericallosal aneurysms. *Neurosurgery* 1992;30:136-7.
10. Dietrich W, Reinprecht A, Gruber A, Czech T. De novo formation and rupture of an azygos pericallosal artery aneurysm. Case report. *J Neurosurg* 2000;93:1062-4.
11. Drake CG. Giant intracranial aneurysms: experience with surgical treatment in 174 patients. *Clin Neurosurg* 1979;26:12-95.
12. Drake CG. Report of World Federation of Neurosurgical Surgeons Committee on a universal Subarachnoid Hemorrhage Grading Scale. *J Neurosurg* 1988;68:985-6.
13. Fankhauser H, Zander E. [Aneurysms of the distal anterior cerebral artery]. *Schweiz Arch Neurol Neurochir Psychiatr* 1978;123:331-57. (Fr with Eng abstract).
14. Farias JP, Trindade AM. Giant distal anterior cerebral artery aneurysm not visualized on angiography: case report. *Surg Neurol* 1997;48:348-51.
15. Foutrakis GN, Yonas H, Scلابassi RJ. Saccular aneurysm formation in curved and bifurcating arteries. *AJNR* 1999;20:1309-17.
16. Fujimoto K, Waga S, Kojima T, Shimosaka S. Aneurysm of distal anterior cerebral artery associated with azygos anterior cerebral artery. *Acta Neurochir (Wien)* 1981;59:65-9.
17. Fukawa O, Fukada N, Aihara H, Wakasa H. [Spontaneous thrombosis of an azygos anterior cerebral artery aneurysm-report of a case]. *No Shinkei Geka* 1982;10:105-11. (Jpn with Eng abstract).
18. Harada K, Kobayashi S, Sigemori M, Watanabe M, Kuramoto S. [Medullary venous malformation with azygos anterior cerebral artery aneurysm: a case report]. *No Shinkei Geka* 1987;15:327-33. (Jpn with English abstract).
19. Hashizume K, Nukui H, Horikoshi T, Kaneko M, Fukamachi A. Giant aneurysm of the azygos anterior cerebral artery associated with acute subdural hematoma. Case report. *Neurol Med Chir (Tokyo)* 1992;32:693-7.
20. Hayashi M, Kobayashi H, Kawano H, Handa Y, Kabuto M. Giant aneurysm of an azygos anterior cerebral artery: report of two cases and review of the literature. *Neurosurgery* 1985;17:341-4.
21. Hernesniemi J, Tapaninaho A, Vapalahti M, Niskanen M, Kari A, Luukkonen M. Saccular aneurysms of the distal anterior cerebral artery and its branches. *Neurosurgery* 1992;31:994-9.
22. Heros RC. Brain resection for exposure of deep extracerebral and paraventricular lesions. *Surg Neurol* 1990;34:188-95.
23. Hosobuchi Y. Direct surgical treatment of giant intracranial aneurysms. *J Neurosurg* 1979;51:743-56.
24. Huber P, Braun J, Hirschmann D, Agyeman JF. Incidence of berry aneurysms of the unpaired pericallosal artery: angiographic study. *Neuroradiology* 1980;19:143-7.
25. Inagawa T. Multiple intracranial aneurysms in elderly patients. *Acta Neurochir (Wien)* 1990;106:119-26.
26. Inci S, Erbenli A, Ozgen T. Aneurysms of the distal anterior cerebral artery. Report of 14 cases and review of the literature. *Surg Neurol* 1998;50:130-40.
27. Ishii T, Yanagibashi Y, Toyoda S, Tsuchida T, Hayakawa K. Aneurysms of distal anterior cerebral artery. *Clin Neurol (Tokyo)* 1974;14:815.
28. Jackson A, Fitzgerald JB, Hartley RWJ, Leonard A, Yates J. CT appearances of haematomas in the corpus callosum in patients with subarachnoid haemorrhage. *Neuroradiology* 1993;35:420-3.
29. Kaneko M, Nukui H, Sasaki H, et al. [Azygos anterior cerebral artery aneurysm]. *Neurol Med Chir (Tokyo)* 1985;25:311-6. (Jpn with Eng abstract).
30. Kanemoto Y, Tanaka Y, Nonaka M, Hironaka Y. Giant aneurysm of the azygos anterior cerebral artery-case report. *Neurol Med Chir (Tokyo)* 2000;40:471-5.
31. Kato Y. [A case of azygos anterior cerebral artery aneurysm]. *Hiroshima Igaku* 1986;39:172, (Jpn) (Abstract).
32. Katz RS, Horoupian DS, Zingesser L. Aneurysm of azygos anterior cerebral artery. *J Neurosurg* 1978;48:804-8.
33. Kayembe KN, Sasahara M, Hazama F. Cerebral aneurysms and variations in the circle of Willis. *Stroke* 1984;15:846-50.
34. Keogh AJ, Sharma RR, Vanner GK. Partial callosal

- resection for pericallosal aneurysms. *Neurosurgery* 1992;31:979-80.
35. Kinoshita K, Matsukado Y. Aneurysms of the distal anterior cerebral artery. *No To Shinkei* 1975;27:1193-202.
 36. Kitamura K. Experience of operative treatment of aneurysms of the anterior communicating artery. In: Kitamura K, ed. *Third Japanese Conference of Special Problems in Neurosurgery. Surgical Treatment of Intracranial Aneurysms*. Tokyo: Upjohn, 1970:67-76.
 37. Kobayashi S, Yuge T, Sugita Y, et al. Azygos anterior cerebral artery aneurysm associated with fenestration of the anterior cerebral artery. *Kurume Med J* 1986;33:149-53.
 38. Kondo A, Koyama T, Ishikawa J, Iwaki K, Yamasaki T. Ruptured aneurysm of an azygos anterior cerebral artery. *Neuroradiology* 1979;17:227-9.
 39. Laitinen L, Snellman A. Aneurysms of the pericallosal artery: a study of 14 cases verified angiographically and treated mainly by direct surgical attack. *J Neurosurg* 1960;17:447-58.
 40. Lau LSW, Bannan E, Tress B. Pseudotumor of the corpus callosum due to subarachnoid haemorrhage from pericallosal aneurysm. *Neuroradiology* 1984;26:67-9.
 41. Lawton MT, Spetzler RF. Management strategies for giant intracranial aneurysm. *Contemp Neurosurg* 1994;16:1-6.
 42. Le May M, Gooding CA. The clinical significance of the azygos anterior cerebral artery (A.C.A.). *Am J Roentgenol Radium Ther Nucl Med* 1966;98:602-10.
 43. Lightfoote JB, Grusd RS, Nalls GA. Azygos anterior cerebral artery mimicking an anterior cerebral artery aneurysm. *AJNR Am J Neuroradiol* 1989;10:S74.
 44. Liou TM, Chang TW, Chang WC. Pulsatile flow through a bifurcation with a cerebrovascular aneurysm. *J Biomech Eng* 1994;116:112-8.
 45. Maiuri F, Corriero G, D'Amico L, Simonetti L. Giant aneurysm of the pericallosal artery. *Neurosurgery* 1990;26:703-6.
 46. Mishima K, Watanabe T, Sasaki T, Saito I, Takakura K. [An infected partially thrombosed giant aneurysm of the azygos anterior cerebral artery]. *No Shinkei Geka* 1990;18:475-81. (Jpn, with Eng abstract).
 47. Mochizuki R, Sakai H, Koyama T, Suzuki T. [Aneurysm of azygos anterior cerebral artery]. *Neurol Med (Tokyo)* 1982;17:406-9. (Jpn).
 48. Mori T, Fujimoto M, Shimada K, Shin H, Sakakibara T, Yamaki T. Kissing aneurysms of distal anterior cerebral arteries demonstrated by magnetic resonance angiography. *Surg Neurol* 1995;43:497-9.
 49. Morley TP, Barr HWK. Giant intracranial aneurysms: diagnosis, course and management. *Clin Neurosurg* 1969;16:73-94.
 50. Nijijima KH, Yonekawa Y, Kawano T. [Bilateral pericallosal artery aneurysms in a mirror position]. *No Shinkei Geka* 1989;17:779-81. (Jpn, with Eng abstract).
 51. Niizuma H, Kwak R, Uchida K, Suzuki J. Aneurysms of the azygos anterior cerebral artery. *Surg Neurol* 1981;15:225-8.
 52. Nitta T, Nakajima K, Maeda M, Ishii S. Completely thrombosed giant aneurysm of the pericallosal artery: case report. *J Comput Tomogr* 1987;11:140-3.
 53. Okawara S. [Aneurysm of the peripheral anterior cerebral artery]. *No To Shinkei* 1968;20:113-20. (Jpn).
 54. Ohno K, Monma S, Suzuki R, Masaoka H, Matsushima Y, Hirakawa K. Saccular aneurysms of the distal anterior cerebral artery. *Neurosurgery* 1990;27:907-12.
 55. O'Neill M, Hope T, Thompson G. Giant intracranial aneurysms: diagnosis with special reference to computerized tomography. *Clin Radiol* 1979;31:27-36.
 56. Pia HW, Zierski J. Giant cerebral aneurysms: problems in treatment. In: Pia HW, Langmaid C, Zierski J, eds. *Cerebral Aneurysms. Advances in Diagnosis and Therapy*. Berlin: Springer, 1979:336-42.
 57. Pool JL, Potts DG. Aneurysms and Arteriovenous Anomalies of the Brain. *Diagnosis and Treatment*. New York: Harper & Row, 1965:139.
 58. Pozzati E, Nuzzo G, Gaist G. Giant aneurysm of the pericallosal artery. *J Neurosurg* 1982;57:566-9.
 59. Preul M, Tampieri D, Leblanc R. Giant aneurysm of the distal anterior cerebral artery: associated with an anterior communicating artery aneurysm and a dural arteriovenous fistula. *Surg Neurol* 1992;38:347-52.
 60. Rossitti S. Shear stress in cerebral arteries carrying saccular aneurysms. *Acta Radiol* 1998;39:711-7.
 61. Schick RM, Rumbaugh CL. Saccular aneurysm of the azygos anterior cerebral artery. *AJNR Am J Neuroradiol* 1989;10:S73.
 62. Shiokawa K, Tanikawa T, Satoh K, et al. [Two cases of giant aneurysms arising from the distal segment of the anterior cerebral circulation]. *No Shinkei Geka* 1993;21:467-72. (Jpn with Eng abstract).
 63. Sindou M, Pelissou-Guyotat I, Mertens P, Keravel Y, Athayde AA. Pericallosal aneurysms. *Surg Neurol* 1988;30:434-40.
 64. Smith RR, Parent AD. End-to-end anastomosis of the anterior cerebral artery after excision of a giant aneurysm: case report. *J Neurosurg* 1982;56:577-80.
 65. Snyckers FD, Drake CG. Aneurysms of the distal anterior cerebral artery. A report on 24 verified cases. *S Afr Med J* 1973;47:1787-91.
 66. Sonntag VKH, Yuan RH, Stein BM. Giant intracranial aneurysms. A review of 13 cases. *Surg Neurol* 1977;8:81-814.
 67. Stehbens WE. Etiology of intracranial berry aneurysms. *J Neurosurg* 1989;70:823-31.
 68. Steiger HJ, Liepsch DW, Poll A, Reulen HJ. Hemodynamic stress in terminal saccular aneurysms: a laser Doppler study. *Heart Vessels* 1988;4:162-9.
 69. Sundt TM Jr., Piepgras DG. Surgical approach to giant intracranial aneurysms. Operative experience with 80 cases. *J Neurosurg* 1979;51:731-42.
 70. Suzuki Y, Kawamata T, Matsumoto H, Kunii N, Matsumoto K. [Large distal anterior cerebral artery aneurysm associated with azygos anterior cerebral artery: case report]. *No Shinkei Geka* 1998;26:935-41. (Jpn with Eng abstract).
 71. Szdzyu D, Lehmann R, Nickel B. Common trunk of the anterior cerebral arteries. *Neuroradiology* 1972;4:51-6.
 72. Traynelis VC, Dunker RO. Interhemispheric approach with callosal resection for distal anterior cerebral artery aneurysms. *J Neurosurg* 1992;77:481-3.
 73. Ture U, Hicdonmez T, Elmaci E. Giant pericallosal artery aneurysm: case report and review of the literature. *Neurosurg Rev* 2001;24:151-5.
 74. Turtz A, Allen D, Koenigsberg R, Goldman HW. Non-

- visualization of a large cerebral aneurysm despite high-resolution magnetic resonance angiography. Case report. *J Neurosurg* 1995;82:294-5.
75. Ujiie H, Liepsch DW, Goetz M, Yamaguchi R, Yonetani H, Takakura K. Hemodynamic study of the anterior communicating artery. *Stroke* 1996;27:2086-93.
 76. Whittle IR, Dorsch NW, Besser M. Giant intracranial aneurysms: diagnosis, management, and outcome. *Surg Neurol* 1984;21:218-30.
 77. Wisoff JH, Flamm ES. Aneurysms of the distal anterior cerebral arteries and associated vascular anomalies. *Neurosurgery* 1987;20:735-41.
 78. Yamagami T, Handa H, Hashimoto N, Nagata H, Watanabe H. Giant aneurysm of the azygos anterior cerebral artery. *Nippon Geka Hokan* 1986;55:777-82.
 79. Yasargil MG. *Microneurosurgery*, Volume I. Stuttgart, New York: G. Thieme Verlag, 1984;305-28.
 80. Yasargil MG. *Microneurosurgery*, Volume II. Stuttgart, New York: G. Thieme Verlag, 1984;224-31.
 81. Yoshimoto T, Uchida K, Suzuki J. Surgical treatment of distal anterior cerebral artery aneurysms. *J Neurosurg* 1979;50:40-4.
 82. Zderkiewicz E, Czochra M, Mosiewicz A. [Aneurysm of the azygos anterior cerebral artery]. *Neurol Neurochir Pol* 1992;26:121-6. (Pol, with Eng abstract).

COMMENTARY

The authors report the successful surgical management of a patient with a ruptured giant pericallosal artery aneurysm associated with an azygos pericallosal artery. This is a very unusual diagnosis, and the authors' illustrations as well as artistic renderings point out the relevant anatomy very nicely. As the authors note, MRI studies are invaluable in determining whether portions of an unusual aneurysm are thrombotic or not. This information can be extremely beneficial, as one would typically be planning for periods of temporary arterial occlusion. Giant aneurysms of the anterior cerebral branches are particularly difficult because the parent vessel is so small. If the aneurysm is thick walled, it can be

extremely difficult to leave enough lumen for orthograde flow through the parent vessel. Intraoperative angiography can be quite helpful in this regard.

H. Hunt Batjer, M.D., F.A.C.S.

*Department of Neurological Surgery
Northwestern University
Chicago, Illinois*

This is a very good case report of the treatment of a patient with a very rare lesion, a giant aneurysm of an azygos pericallosal artery. The authors review their evaluation and treatment of this patient and should be congratulated for their surgical result despite the patient's ultimate death from nonsurgical causes.

They provide a thorough review of the relevant anatomical, biophysical, and epidemiological factors relevant to these lesions. In particular, their discussion of the anatomical variants of the distal anterior cerebral arteries is excellent.

The high incidence of multiple aneurysms in these patients fits currently held hypotheses that shear stress plays a major role in the origin of these and other berry aneurysms. Perhaps more interesting is the fact that giant aneurysms are rare in this setting, where there is almost certainly high shear. This low incidence of giant aneurysms supports the idea that while shear is important in aneurysm initiation, other mechanisms are more important in aneurysm growth.

Phillip Dickey, M.D.

Department of Neurosurgery

Purushothaman Kailasnath, Ph.D.

*Department of Diagnostic Radiology
Yale University*

The campaign of prosecutions of nursing homes for quality will probably spill over to hospitals and physicians' practices, according to Jim Sheehan, Assoc. U.S. Attorney for the Eastern District of Pennsylvania (*Medicare Compliance Alert* 8/4/03).

—AAPS NEWS, VOLUME 59, NO. 9, SEPTEMBER 2003